Ann Natl Acad Med Sci (India), **43(3)**: 75-88, 2007

Spinal Surgery in India : Present, Past and Future

P.K. Dave
Former Director and Professor & Head, Department of Orthopaedics, All India Institute of Medical Sciences, New Delhi-110029, India.

Abstract

During the last few decades, a lot of recent advances in spinal surgery have taken place. Spinal fusion is an extremely useful procedure to stabilize the unstable spine due to traumatic, neoplastic, congenital or degenerative conditions. Spinal instrumentation corrects deformity and reduces pseudarthrosis rates at the price of slightly increased operative complication rates. In future new implants system will continue to involve with emphasis on improved fixation, precision of insertion and safety. Prevention of deformities by education, careful screening programmes and early treatments would go a long way in proper treatment of congenital scoliosis in children.

"Whatever medicine there is on the Sindhu,

On the Asikni, in the seas, on the mountains;

Seeing it, you carry all on your bodies.

Bless us with it! Down to the earth, O Maruts,

What hurts our sick ones, - Straighten what is crooked."

Spine surgery in India in the early 50s and 60s was very much in infancy; it was only in late 1960s and 70s. spine surgery started in a significant manner. The earliest stalwarts who popularized spine surgery and were considered pioneers were the following:

Correspondence: Dr. P.K Dave, Chairman, Advisory Board, Rockland Hospital, B-33-34, Qutab Institutional Area, New Delhi-110016. E-mail: rocklandhospital@yahoo.co.in
Academy Oration, 2005-2006, delivered at the Annual Meeting at Hyderabad, 2006.

- Dr. K. T. Dholakia
- Dr. K.S. Masalawala
- Prof. Prakash Chandra
- Dr. Dinubhai Patel

The pioneers who popularized anterior approach to spine were Prof. Prakash Chandra of All India Institutes of Medical Sciences and Dr. K.S. Masalawala from Bombay. Tuberculosis of spine was extremely common and both Chandra & Masalawala attacked the vertebral body lesions from the front.

During the last few decades, a lot of recent advances in spinal surgery have taken place. A study of the Indian mythology is replete with correction of spinal deformity by Lord Krishna wherein he cured "Kubja" of the spinal deformity. An excellent account of the history of treatment of scoliosis through the ages is mentioned in the monograph by Robert Roaf (1).

The following table gives the whole gamut of classical spine and modern surgery.

	Classical	Modern
Scoliosis	**Harrington**	**Segmental Correction**
	Open	**Endoscopic ant. Release**
Trauma	**Ligamentotaxis**	**Restoration of biomechanics**
Listhesis	**In situ fusion**	**Reduction & Global Fusion**
Fusion	**Tricortical grafts**	**Cages**
	Fibular Grafts	
Osteoporotic	**Braces**	**Vertebroplasty/ Kyphoplasty**
Fractures		
Tumor	**Radiotherapy**	**Total Corpectomy**
		+
	Chemotherapy	**Instrumentation**

The correction of Scoliosis surgery was undertaken by surgeons of United Kingdom like Robert Roaf, JIP James and Charles Manning. The scoliosis was corrected both by anterior and posterior approach. On going through the literature and pictures associated with scoliosis it was observed that the basic design of correcting instruments has not really changed at all.

In India the treatment of scoliosis had a very chequered past. The natural history of the disease was not understood by the surgeons as well as the general practitioners. Therefore the patients were brought to the clinics at a very late stage in life when the curves had become very rigid. The fact is that it is easier to control the scoliotic curve from increasing rather than to correct already present rigid and deformed spinal curve.

The fundamental principal of scoliotic surgery is to recognize the early curve pattern, to prevent it from increasing and to correct it when adolescent growth stops; the residual curve can be corrected by surgical means and have the spine fused. The whole basis of corrective scoliotic surgery is to have a proper spinal fusion with or without instrumentation. Spinal fusion entails proper decortiacation of the spinous process, laminae and transverse processes augmented by generous amount of bone graft taken from the iliac crest. The facet joints are also excised in this process for a proper spinal fusion. The harvesting of the bone graft from the iliac crest has to be done by meticulous exposure from the outer table so as to get adequate cancellous bone graft which would ensure proper healing and fusion. While harvesting the graft from the iliac crest no dead space should be left.

In the earliest stages at our setup at All India Institutes of Medical Science we used the following approach. We controlled and corrected the curve by applying a Milwankee brace; when the child had attained a good height and/ or was nearing the stoppage of adolescent growth we applied a Risser's localizer cast for final correction of the scoliotic curve and the spinal fusion was carried out through a window in the plaster jacket. This was the method used in the treatment and correction of scoliosis in the earlier years. The western text books had mentioned the age of spinal fusion as 10 years but most children in our country have not attained a good height at the age of ten we deferred spinal fusion for a later date.

After this came an era of instrumentation of the spine. Suddenly there was an avalanche of fixation devices both anterior and posterior. The decision to choose a particular type of implant depended upon the biomechanical aspect, its availability, familiarity and the expanse. Initially the posterior spinal fixations system were in vogue and are listed below.

Post. Spinal Fixation Systems

- **Hook – Rod Systems**
  - **Harrington**
- **Sublaminar Wire – Rod System**
  - **Luque**
  - **Hartshill**
  - **Harri Luque**

- **Pedicular Screw System**
  - **a. Plate System**
  - **Steffe**
  - **Domino**
  - **b. Rod Sytems**
  - **Fixator Internae (AO)**
  - **C.D./ Moss. Miami/ USIS**
- **Pedicular Screw - Hook - Rod System**
  - **Coteral-Debousset**
  - **Moss-Miami**
  - **USIS**
  - **Munster**
- **Pedicular Screw - Hook - Wires - Rod System**
  - **Lioln**

However, the most common fixation system was the distraction Harrington instrumentation which was popularized by Paul Harrington. Indeed it was considered the gold standard and was much in vogue in the early sixties. The principle of Harrington instrumentation was indirect reduction affected by ligamentotaxis. It had a distraction and a compression assembly. Subsequently many surgeons found the compresson assembly not to be of much use and were discarded. However in spite of its popularity certain disadvantages began to appear after a longer follow up. It involved a large number of motion segments, caused a flat back syndrome, had high stress level at the hook lamina junction and had a propensity to break at the rod-ratchet junction. Occasionally overzealous distraction by an outrigger caused paralysis in some cases (2) which can be reversed by removing the implant immediately. (3)

In case of a double scoliotic curve two rods should not be applied, because the intervening area develops pseudoarthrosis. In such cases a dollar sign single rod should be applied. We also used Harrington rod as a second surgery after doing an anterior loosening of the curve through a transthoracic (for a dorsal curve) or a thoraco-abdominal approach (for a dorso-lumbar curve). After an anterior loosening the patients were kept on halo-traction with the body weight acting as counter traction for a period of 2 weeks. This procedure improved the rotation of the curve considerably and then a 2nd stage Harrington instrumentation was done. The following complications and disadvantages are reported in literature.

Harrington Instrumentation

- Major correcting force is a distraction force
- Incidence of neurological injury is < 1%.
- Pseudoarthrosis rate < 10%
- Disadvantage

- Immobilization in brace for 6-9 months.
- Average curve correction is 50%.
- Obliteration of lumbar lordosis.
- Does not help in thoracic kyphosis.
- Fracture of lamina and dislocation of hooks.

To obviate the stress on the hooks in Harrington instrumentation, a concept of segmental spine fixation was developed by Luque (6) using sublaminar passage of wires. Its advantage was restoration of rotational alignment. However this fixation does not support axial load and corrective distraction or compression is not possible.

A further modification was a combination of Harrington rod and Luque instrumentation i.e. Luque segmental wiring to Harrington-rod-hook complex. This procedure had an increased risk of neural injury.

The advantages and disadvantages of segmental spinal instrumentation are given below

Advantages of segmental spinal instrumentation

- Rigid fixation
- Greater stability
- Unlimited correction
- Maintenance of sagittal contours
- More effective for short curves

Disadvantages of Segmental Spinal Instrumentation

Wire Failure (Common Causes)

- Kinking
- Over stretching while operating on previously under corrected curves
- Fatigue from movement following insufficient immobilization or excessive stress during wire placement.

High Incidence of Neural Injuries

- Over Distraction
- Nerve Root tethering
- Excessive deep wire penetration

Poor Correction of Rotational Deformities

A further modification of posterior segmental instrumentation was reported by Cotrel Debousset instrumentation. This system was unique as it utilized hooks and pedicle screws for fixation, the latter particularly used in the dorsal, lumbar and lumbar spine.

Cotrel Dubousset Instrumentation

- Idiopathic scoliosis is the best indication
- Unequalled corrections of scoliosis, thoracic lordosis and hypokyphosis.
- Minimal angular losses at follow up.
- Post- operative external support not needed.

Relative advantages of different systems are as follows:

Qualities of Different Posterior Sytems (II)

	STABILITY	SAFETY	TECHNICAL EASE	POST OF IMMOBILISATION
HARRINGTON Inst.	+	++++	+++	+
HARRI LUQUE	++	+	+	++
LUQUE	++	+	++	++
DRUMMONDS	+++	+++	++	++
COTREL DUBOUSSET	+++	++	+	++

A further modification of this system was carried in the Moss-Miami technique which was somewhat similar in concept and design but was quite sturdy and reliable.

Multihook Segmental Instrumentation

- Cortel Dubousset (CD) and Texas Scottish Rite Hospital (TSRH) systems.
- Provide multiple points of fixation to the spine and allow both compression and distraction on the same rod.
- Result on
  - Improved correction.
  - Preservation of lumbar lordosis.
  - Preservation in rib prominence deformity because of derotation defect.
  - No postoperative immobilization.

Pedicle Screw Segmental Instrumentation

- Steffe
  - Force nucleus concept.
  - Pedicles: Provide strong fixation.
  - Lesser number of motion segment involved.
  - Better control of axial, bending & shearing forces.
- Disadvantages
  - 10 - 15 % pseudoarthrosis rate anteriorly.

Neglected Rigid Curves

A large number of patients came to our clinics with curves which were rigid and totally unacceptable cosmetically. In addition to pain and cardiopulmonary decompensation, it caused a deep psychological distress in those children. The strategy to deal with these rigid

neglected curves was to perform anterior loosening and apply a corrective implant either anteriorly or posteriorly.

Initially it was Dwyer's instrumentation (7) which was used to correct the curve. Dwyer's (8) instrumentation was a device which had a cable attached to the vertebral bodies with large screws after performing anterior release. Initially it seemed to be promising but had considerable limitations. It was not a very rigid fixation, needed post operative immobilization, cable fractures were not uncommon and iatrogenic kyphosis by compression was common without derotation on the convex side. Further move it could only be done in adults and that too in lumbar and dorso-lumbar curves. Some complications like pseudarthrosis, paraplegia and loss of correction had also been reported. (9).

Subsequently the anterior approach surgery for correction of scoliosis was modified by Zeilke's instrumentation. The ideal indication for Zeilke's instrumentation is a lumbar or thoracolumbar curve. The thoracolumbar curve is exposed by excising the 10th rib and dividing the diaphragm at its periphery. The instrumentation uses a system of screws, a compression rod, hex nuts for controlling the rod into the screws and a derotation bar. By moving the bar gradually the convexity is corrected. A great advantage of this technique is sound biomechanics and a significant correction of rotation.

Humpectomy: In some of the very rigid curves where surgical correction, either by anterior or posterior approach is not feasible humpectonomy is a good option since it gives a very good result cosmetically. Before doing a humpectomy it is essential to take a silhouette view of ribs. In cases of rotation of the spine the vertebral bodies rotate in the hollow of ribs. In such a case excision of the rib would not give any cosmetic benefit. However if the vertebral body is not rotated excision of the prominent part of ribs shows a good cosmetic result.

Congenital Scoliosis

In our series congenital scoliosis was extremely common possibly because ours was a referral centre attracting a large number of patients. Congenital scoliosis can be classified into subgroups depending upon the type of congenital anomaly present. (12)

1) Failure of formation: it could be partial unilateral failure of formation (Wedge vertebra) or a complete unilateral failure (hemivertebra).
2) Failure of segmentation
   a) Unilateral failure of segmentation causing a unilateral unsegmented bar.
   b) Bilateral failure of segmentation (block fusion).
3) Multiple anomalies.

In some cases of congenital spinal deformity the posterior spinal elements

are deficient causing spina bifida or a meningomyelococle. In a study by John Hall (reported by Winter 1973 in a personal communication) (12) 101 cases out of a total of 130 patients had scoliosis, which were analysed after a follow up to the age of 18 yrs or older.

Many of these cases of congenital scoliosis there were other associated anomalies pertaining to other organs which also need to be thoroughly investigated. Congenital cardiac and genito urinary anomalies are common and need investigation and treatment. Klippel-Feil syndrome, Sprengel's deformity and other musculo-skeletal anomalies are often associated with congenital scoliosis.

Diastematomyelia is a common entity seen in congenital scoliosis and must be suspected if there is a hairy patch on the back, extradural lipomata, spina bifida or if neurological changes are present (13). Diastematomyelia is an osseous-cartilaginuos mass arising from the posterior aspect of the vertebral body. The spinal cord divides, goes round this osseous bar and rejoins after some distance. An MRI is a useful diagnostic tool and must be carried out on slightest suspicion particularly if there are signs of paresis. Diastematomyelia should be removed; otherwise as the child grows neurological deficit would increase. On no account scoliosis correction by distraction either by Harrington instrumentation or halo-pelvic traction may be undertaken before diastematomyelia is tackled. Interestingly enough we have seen diastematomyelia in seemingly clinically apparent idiopathic scoliosis as part of a research project on routine MRI examination.

A hemivertebra or a wedge vertebra or a spine with multiple deformities must be kept on observation for the simple reason that the scoliotic curve may not increase. Should the curve increase, which it invariably does if there is a unilateral unsegmented bar on the concavity, spinal fusion may be carried out to stop further progression of the curve. All cases of congenital scoliosis must be kept on periodic radiological examination.

Paralytic Scoliosis

The commonest cause of paralytic scoliosis in our country is due to anterior poliomyelitis. The curve deteriorates very quickly after the acute stage subsides. It is usually a long curve and is due to muscle imbalance. However there is always a compensatory curve above and below the structural curve. (14).

Other causes of paralytic scoliosis also have to be considered like muscular dystrophy, cerebral palsy, syringomyelia Friedreich's ataxia, meningomyelocoele, arthrogriposis multiplex congenita.

The principle of treatment of paralytic scoliosis is to maintain correction of the curve in a Milwankee

brace or a localizer cast. When the child has reached growth maturity spinal instrumentation and fusion should be done. Some paralytic curves even at the time of maturity are very flexible and can be corrected and stabilized by posterior instrumentation. Of course they need external immobilization in the post operative period. If the patient presents with a severe rigid curve a two stage surgery gives very satisfying results.

1st stage: Anterior release and halo sliding traction.

2nd stage: Posterior instrumentation and fusion.

In some cases we have we have done an anterior release and instrumentation followed by posterior instrumentation and fusion. This latter approach gives a very satisfactory rigid fixation and obviates the need for an external support like a plaster jacket.

Over the years technological advances have made the scoliosis surgery easier, more secure and reliable. Single lung anaesthesia, better intra operative and post operative care including intensive care unit facilities have made combined procedure under single anaesthesia possible. Video assisted thoracoscopic surgery has been made possible. Laproscopic anterior spinal fusion following loosening of the curve is a distinct possibility and would become more common in future.

The data from the scoliosis clinic at All India Institute of Medical Sciences is as follows:

Curve Pattern

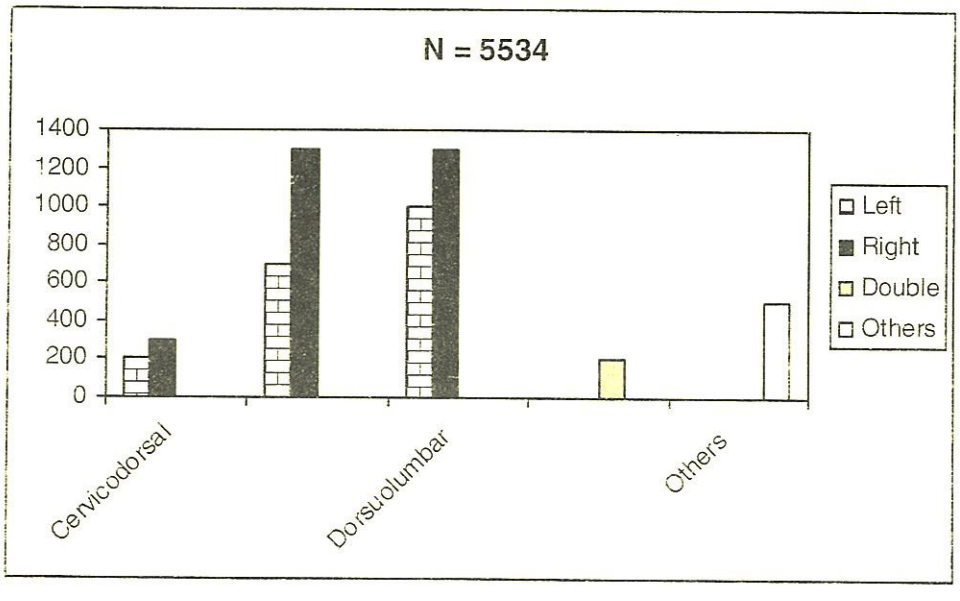

Aetiology and Sex distribution

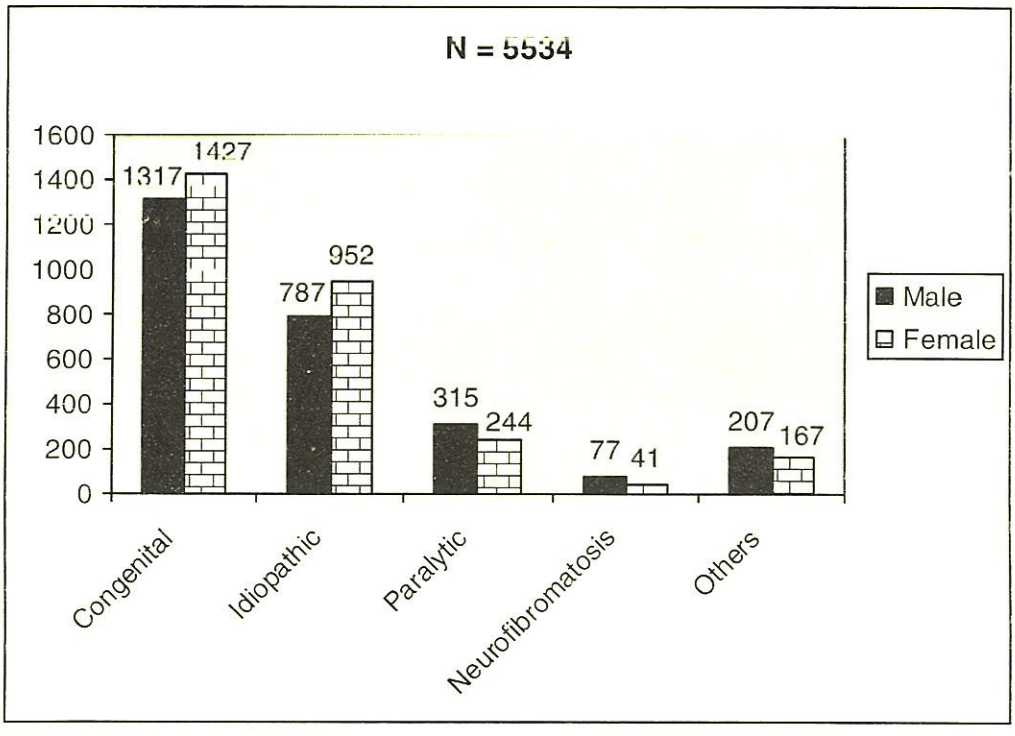

SCOLIOSIS TREATMENT AIIMS EXPERIENCE	
Jacket+Localizer Cast	87
Ant. Loosening	52
Post Fusion	178
Post Instrumentation	192
Total	**509**

Experimental Scoliosis

The aetiopathology of idiopathic scoliosis has never been explained satisfactorily. Many attempts had been made to establish a suitable experimental model (15, 16) but the most consistently reproducible one was reported by Langen skiold & Michelsson (16) in rabbits. We attempted to produce scoliosis in monkeys because of their semi upright posture and nearness to human beings on the phylogenetic scale. It was thought that this model would be somewhat comparable to human idiopathic scoliosis.

Scoliosis in our experiments was produced by excision of medial end of ribs and costo-transverse ligaments. One sided excision of these structures resulted in scoliosis which disappeared at the end of six weeks. In monkeys when

the ribs were excised on the opposite side at the end of six weeks a demonstrable structural curve appeared which was rigid and did not disappear on lifting the animals. To the best of our knowledge this is the first report on production of scoliosis in monkeys although Stilwell (17) in monkeys and Robin & Stein (15) in baboons had tried unsuccessfully to produce experimental scoliosis.

ADVANCES IN SURGERY IN OTHER SPINAL CONDITIONS

i. Lumbar spondylosis

Laproscopic spinal fusion can be carried using a transperitoneal (for L5-S1 level) or retroperioneal approach (for L1-L4 level) using a balloon dilation or retroperitoneal gas technique. Of course the requirement of special instruments would be there. Laproscopic anterior spinal fusion is indicated in symptomatic degenerative disc disease or internal disc disruption at one or two levels. It is strictly contra indicated in severely osteoporotic patients who are more than 65 yrs of age and have more than 2 level disease.

Percutaneous interbody fusion, video assisted postero lateral lumbar arthrodesis have also been developed. Latter is suitable for uninstrumented lumbar arthrodesis for one or two levels. It really has low morbidity, less cost and hospital stay.

Disc surgery: Laminotomy fenestrations have been done routinely. Yet percentaneous disc excision, laser evaporation and micro lumbar discectomy are the recent advances and have given good results.

Kyphotic deformities correction has changed from the times of prolonged recumbency and plaster cast immobilization to excellent correction using segmental fixation and early mobility.

Cages have been introduced in the last decade to enhance interbody fusion rate. Cages support the fusion mass during creeping substitution phase. It is a load sharing device and indirectly maintains neuroforaminal distraction by maintaining disc space height. Cages are useful in spinal traumatic conditions, degenerative disorders, spondylolisthesis, tuberculosis of spine and tumors.

Spinal trauma: its treatment is the restoration of spine biomechanics; 80% stresses pass through anterior column and 20% through the posterior column. In case of anterior column unstable injury partial corpectomy, decompression, graft/cage fixation and anterior stabilization is resorted to. In both anterior and posterior column injury, combined anterior and posterior column reconstruction with anterior and posterior instrumentation and fusion after decompression is the choice of treatment.

Tuberculosis of spine: In the past tuberculosis paraplegia was treated by

decompression and bone grafting. The scenario has changed to the modern concept of thorough decompression, debridement, bone grafting and instrumentation for maintenance and deformity correction.

SCOLIOSIS

AIIMS DATABASE

Aetiological Pattern

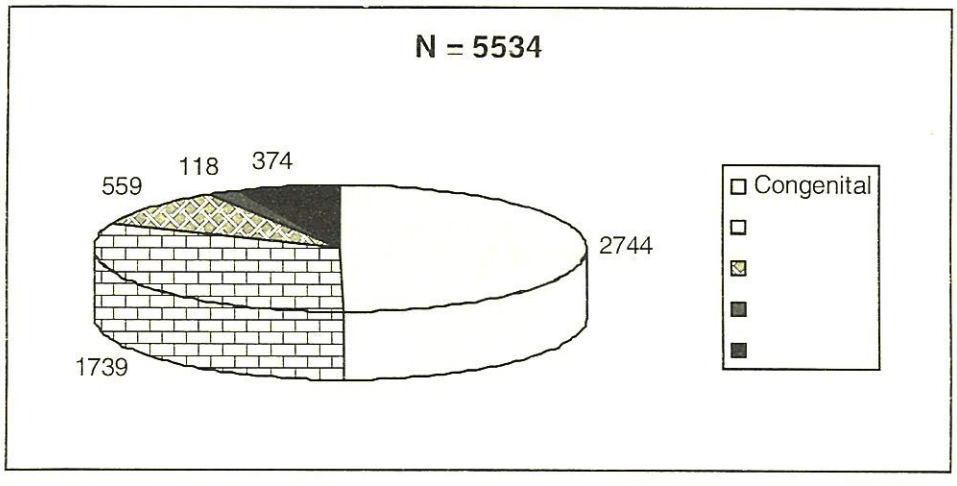

Number of patients of scoliosis 1972 – June 2000

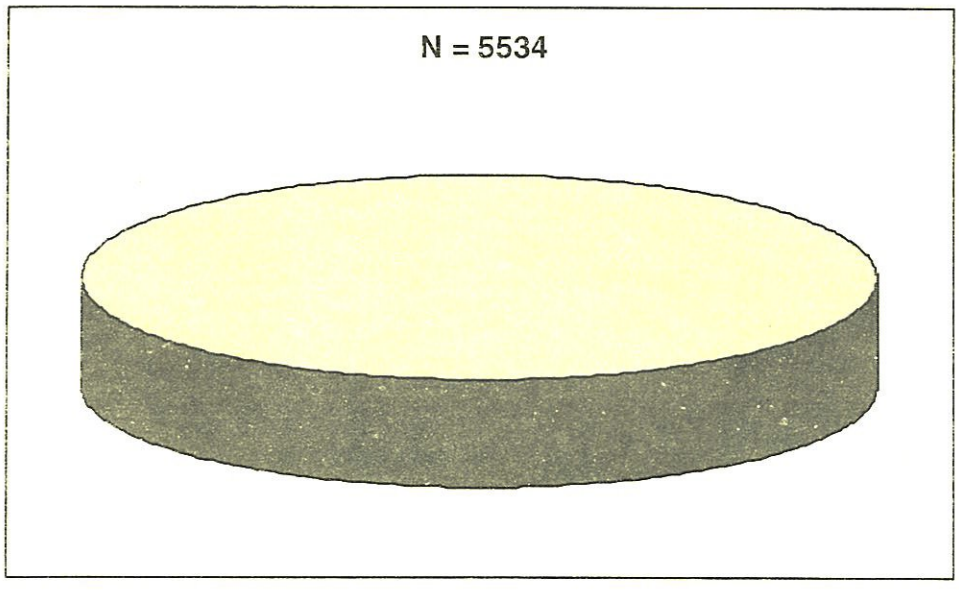

The treatment of osteoporosis with vertebral collapse has also undergone a change. Vertebral fractures are the most common complication of osteoporosis. While medical treatment continues to be the sheet anchor of treatment, in some cases where there is no response to NSAIDS, calcitionin etc and there is progressive loss of physiological spinal alignment kyphoplasty/ vertebroplasty offers a very viable option of treatment (18). Contra indications are in cases of serious medical conditions. Also in cases of severe compression fracture with or without neurological deficit percutaneous vertebroplasty is contra indicated. More than 2 or 3 vertebral augmentation should not be done.

The two basic requirements for spine surgery are to have a proper team of surgeon, anesthesist, orthotist and nursing personnel. Sound anesthesia technique is also extremely important for spine surgery.

CONCLUSIONS

Spinal fusion is an extremely useful procedure to stabilize the unstable spine due to traumatic, neoplastic, congenital or degenerative conditions.

Spinal instrumentation corrects deformity and reduces pseudarthrosis rates at the price of slightly increased operative complication rates.

Spinal instrumentation will fail with time unless adequate bony fusion occurs

Screws, plates/ rods, cages, "front-back-front" approach, etc. are fine and look very appealing but feasibility/ applicability and affordability are important considerations.

In future new implants system will continue to involve with emphasis on improved fixation, precision of insertion and safety. Prevention of deformities by an education, careful screening programmes and early treatments would go a long way in proper treatment of these children.

Every Valley shall be exalted
And every mountain and hill
Shall be made low: and the
Crooked shall be made straight

Isaiah 40.4

References

1. Roaf. R (1980) Spinal Deformities Pitman Medical Ltd., Kent UK.
2. Harrington, P.R. (1962) Treatment of scoliosis. Correction and internal fixation by spine instrumentation. *J.Bone. Jt. Surgery* **44 A**, 591-610.
3. Harrington P.R & Dickson J.H. (1973) an eleven year clinical investigation of Harrington instrumentation. A preliminary report of 578 cases. *Clin. Orthop.* **93**:113-30.

4. Macewen, G.D., Bunnell, W.P. & Spiram, K. (1975) acute neurological complications in the treatment of scoliosis. *J. Bone. Jt. Surg* **57 A**, 404-408.

5. J. I. P. James, Zorab, P.A & Wynee-Davies. R (1976) Scoliosis. P 315 Edinburgh, London & New York. Churchill-Livingstone.

6. Luque, E.R. (1982) the anatomic basis & development of segmental spine instrumentation. *Spine* **7**:256-259.

7. Dwyer A.F. (1969). An anterior approach to scoliosis. *J. Western Pacific Orthop. Assoc*, **6(1)**, 63-96.

8. Dwyer, A.F., Newton, N.C. and Sherwood, A.A. (1969). An anterior approach to scoliosis. *Clin.Orthop.* **62**:192-202.

9. Dwyer, A.F. & Schafer, M.F. (1974) anterior approach to scoliosis. Results of treatment in 51 cases. *J. Bone. Jt. Surg* **56 B**, 218-24.

10. James J.I.P., Zorab, P.A. & Wynne-Davies, R (1976) Scoliosis. Edinburgh, London & New York Churchill-Livingstone.

11. Zielke, K., Berthet A: Ventrale Derotations spondylodese vorlauger Bericht uber 58 Faille Beit *Orthop Traumatol* **25:** 85-103, 1978.

12. Winter, R.B. (1973) congenital spinal deformity: Natural History and treatment. Israel *Journal of Medical Science*. **Vol 9**. No.6 719-727.

13. Gillepsie, R., Faithful, D., Roth, A & Hall. J.E. (1973) Intraspinal anamolies in congenital scoliosis *Clin.Orth.* **93**:103-9.

14. James J.I.P (1956) Paralytic Scoliosis. *J. bone, Jt. Surg.* **38 B,** 660-85.

15. Robin G.C. & Stein M. (1975) experimental scoliosis in primates. Failure of a technique *J.Bone. Jt. Surg* **57 - B**, 142 – 145.

16. Nordwall. A. (1973) Studies in idiopathic scoliosis relevant to etiology. Conservative & operative treatment *Acta. Orthop. Scand.* Suppl.150.

17. Langenskiold, A. & Michelsson J.E (1962) Pathogenesis of experimental progressive scoliosis. *Acta Othop. Scand.* Suppl 59.

18. Stilwell, D.L. (1962) structural deformities of vertebrae. Bone adaptation & modeling in experimental scoliosis and kyphosis. *J. Bone. Jt. Surg.* **44-A**, 611-634.

19. Garfin S.R., Yuan M.A. & Reiley M A (2001). New technologies in spine: Kyphoplasty & vertebroplasty for the treatment of painful osteoporotic compression fractures. *Spine* **26**: 1511-1515.