



Challenges with Adjuvant Radiation for Intracranial Chondrosarcoma in Pregnancy

Arun Yadav¹ Shikha Goyal¹ Renu Madan¹ Ranjit Singh¹ Aarti Chitkara² Divya Khosla¹

¹Department of Radiotherapy and Oncology, Postgraduate Institute of Medical Education and Research, Chandigarh, India

²Department of Obstetrics and Gynecology, Postgraduate Institute of Medical Education and Research, Chandigarh, India

Address for correspondence Shikha Goyal, MD, DNB, Department of Radiotherapy and Oncology, Post Graduate Institute of Medical Education and Research, Chandigarh 160015, India (e-mail: drshikhagoyal@gmail.com).

Ann Natl Acad Med Sci (India) 2023;59:49–54.

Abstract

Keywords

- ▶ brain neoplasms
- ▶ chondrosarcoma
- ▶ radiation therapy
- ▶ pregnancy complications
- ▶ teratogenesis

Background Managing a brain tumor during pregnancy is a highly confusing and challenging situation, complicated by several technical, medical, ethical, and sociocultural concerns. The interests of the mother and child are often pitted against each other, for which legal opinion may occasionally be needed.

Case Report We present the report of a young lady with intracranial well-differentiated chondrosarcoma who was determined to be pregnant in the immediate postoperative period. We discuss the management of challenges and dilemmas in devising optimum therapy, and the modifications and care required at each step to help safeguard maternal and fetal health. Risks with therapeutic radiation and measures to assess and pre-empt fetal doses that may assist decision-making are also discussed.

Conclusion Radiation therapy during pregnancy is challenging and requires multidisciplinary involvement and psychosocial support for the patient and family.

Introduction

Surveillance, epidemiology and end results 21 age-adjusted statistics (2013–2017) place the annual incidence of brain neoplasms at 5.4 per 100,000 women; 16% of these occur in the reproductive age group.¹ Nearly 90 women are diagnosed with brain tumors during pregnancy per year in the United States.² Depending on histology, extent, and expected prognosis, some of these may merit immediate or early treatment of brain tumor, with special considerations for maternal and fetal safety depending on the period of gestation (POG). The physiological state of pregnancy itself may aggravate symptoms due to increased plasma volume, hypervascularity, and hormonal stimulation, sometimes precipitating pregnancy complications or obstetric emergencies. If the management protocol includes radiation therapy (RT),

the risks of teratogenicity, growth retardation, mental retardation, and childhood cancers have to be weighed against the benefits of disease control in the mother creating a mutual conflict of interest.

We discuss the management challenges in a pregnant lady with intracranial chondrosarcoma, referred for adjuvant RT.

Case Presentation

A 27-year-old nulliparous woman presented to the neurosurgeon with headache and vomiting for 6 months and sudden onset right-sided weakness for 2 months. She had memory disturbances, slurred speech, and ptosis left eye. There was no history of trauma, bowel or bladder disturbances, seizures, or loss of consciousness. Clinical examination

article published online
February 6, 2023

DOI <https://doi.org/10.1055/s-0042-1758225>.
ISSN 0379-038X.

© 2023. National Academy of Medical Sciences (India). All rights reserved.

This is an open access article published by Thieme under the terms of the Creative Commons Attribution-NonDerivative-NonCommercial-License, permitting copying and reproduction so long as the original work is given appropriate credit. Contents may not be used for commercial purposes, or adapted, remixed, transformed or built upon. (<https://creativecommons.org/licenses/by-nc-nd/4.0/>)

Thieme Medical and Scientific Publishers Pvt. Ltd., A-12, 2nd Floor, Sector 2, Noida-201301 UP, India

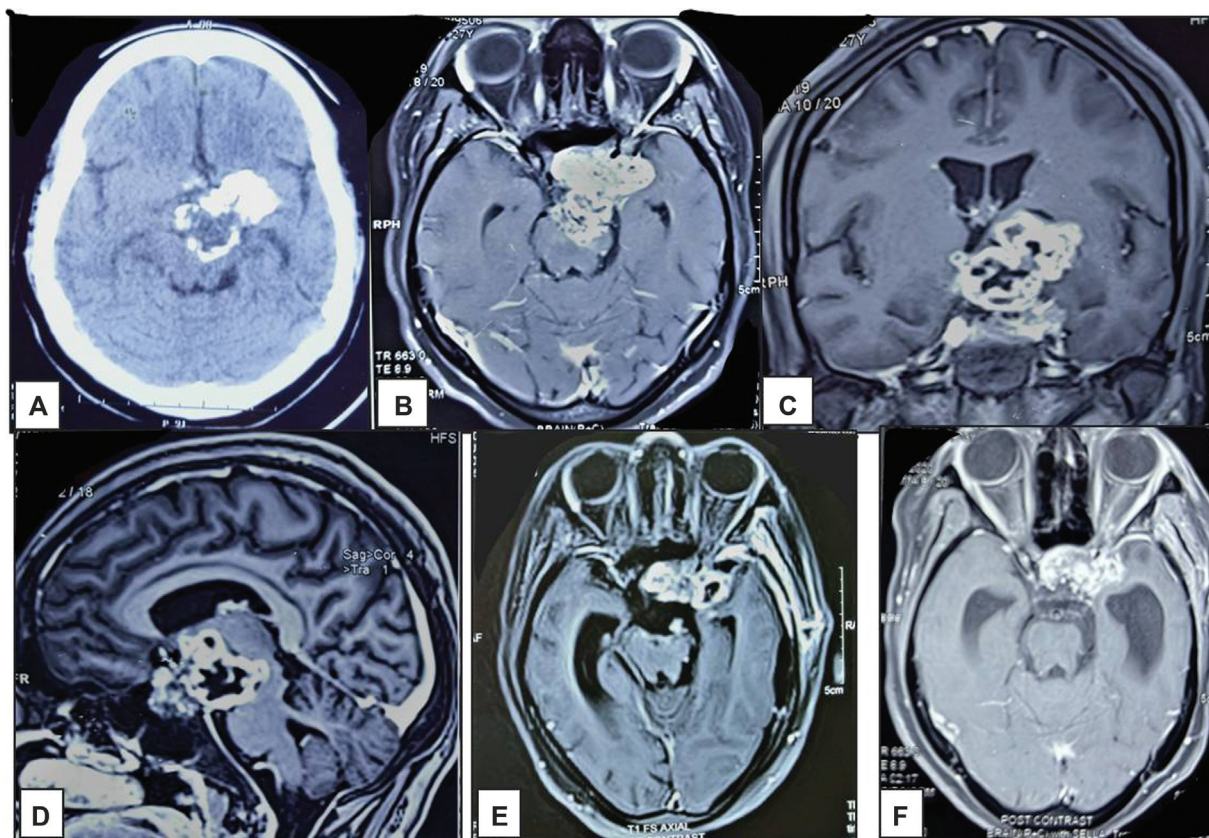


Fig. 1 (A) Baseline computed tomography brain showing a large heterogeneous calcified lobulated swelling in sellar-suprasellar region with extension to left parasellar region and brainstem. Contrast-enhanced magnetic resonance imaging (MRI) in (B) axial, (C) coronal, and (D) sagittal sections show a multilobulated heterogeneously enhancing solid-cystic lesion involving sella, suprasellar and left parasellar region, left internal/external capsules, basal ganglia and frontal periventricular regions. Pituitary gland and optic chiasm are not seen separately. The mass is eroding left lateral wall of sella to extend into left cavernous sinus and extra-axial extradural temporal lobe. Left internal carotid artery is completely encased and narrowed. Posteriorly, the lesion extends into interpeduncular cistern with left posterior midbrain infiltration. Moderate dilatation of right lateral and third ventricle seen. (E) Postoperative MRI showing residual disease with reduction in mass effect (F) MRI at 30 months postradiotherapy with stable disease.

revealed an average build patient with Glasgow coma scale E4V5M6, right hemiparesis (upper limb 2/5, lower limb 3/5), reduced vision in both eyes (both pupils reacting to light, finger counting at 2 m in right eye and 1 m in left eye), and left oculomotor palsy. She had partial recent memory loss. Contrast-enhanced magnetic resonance imaging (CEMRI) of the brain showed a large sellar-suprasellar lesion with engulfed optic chiasm (→Fig. 1A–D). Differential diagnoses considered were clival chordoma, meningioma, and craniopharyngioma.

She underwent craniotomy and subtotal tumor excision. Intraoperatively, it was a rock-hard tumor, with calcification extending from Sylvian fissure involving sella, parasellar region, cavernous sinuses, and ambient cisterns. Postoperative histopathology suggested well-differentiated chondrosarcoma, with S-100 strongly positive.

Postoperative computed tomography (CT) scan showed significant residual disease, hence, a radiation oncology opinion was sought. At this stage, she had a performance status (PS) of Eastern Cooperative Oncology Group 3, right facial palsy, right hemiparesis (upper limb 0/5, lower limb 1/5, decreased vision left eye (finger counting at 0.3 m) and stable right eye vision, psychiatric and memory disturbances, and slurred

speech. Postoperative MRI revealed a large ill-defined residual heterogeneous mass with a 10 mm midline shift. Optic chiasm was infiltrated (→Fig. 1E). Fundus examination showed bilateral optic atrophy compounded by surgical insult. The patient had developed postoperative panhypopituitarism, including diabetes insipidus and amenorrhea. Details of her last menstrual period seemed unreliable due to psychiatric disturbance. Urine pregnancy test was advised prior to advising adjuvant RT and returned positive. High-risk obstetric clinic evaluation after the positive urine pregnancy test confirmed the pregnancy with POG 23 to 24 weeks.

The following factors were considered while making further management decisions:

- Favoring early RT to delay disease progression: Young patient, good prognosis histology, large residual, multiple cranial nerve involvement, contribution of mass effect to neurologic/psychiatric/hormonal deficits leading to poor PS.
- Favoring delayed RT to allow fetal maturity: RT exposure linked with risk of teratogenesis, mental and growth retardation, fetal carcinogenesis.
- Favoring medical termination of pregnancy (MTP): Low PS, patient dependent and incapable of self-care

(hemiparesis, speech problems, hormonal imbalances, poor vision in left eye, psychiatric and memory disturbances), or taking care of pregnancy on her own, possible prior exposure to multiple teratogens during the first trimester (multiple CT scans and X-rays, drugs including antiepileptics, anesthetic agents, possible fetal hypoxia) and additional risk with RT.

- Against MTP: Primigravida, expected fetal exposure with imaging and cranial radiation within deterministic effects tolerance, medicolegal concerns against termination of pregnancy beyond 20 weeks.

After discussion with the patient's family and deliberation in a special multidisciplinary board highlighting the patient's poor general condition to sustain the pregnancy, a court order was obtained for MTP at 26 to 27 weeks POG, considering a grave risk to the mother with the delay of adjuvant treatment. There was an ethical dilemma of labeling this as MTP (per court orders) or induced delivery because of fetal salvageability. An antenatal scan showed a viable fetus (weight ~1,000 g). The patient underwent induced vaginal delivery with Cerviprime at 27⁺⁶ weeks POG. A live girl child (birth weight 1 kg, Apgar score of 6,8) was born; she needed neonatal intensive care unit care for the management of respiratory distress, where she stayed till her eventual demise at 2.5 months due to persistent pneumonia. In the postpartum period, the patient's psychiatric problems, speech, and upper limb power (¾) improved. Within a week of delivery, adjuvant therapy was planned. Since she had a sellar residual calcified tumor with engulfment and distortion of the optic chiasm and left optic canal, which were challenging to delineate even on thin-section CEMRI, we had to limit the deliverable dose to 5,400 centigray (cGy) in 27 fractions over 5.5 weeks. Treatment was delivered using a noncoplanar three-field beam arrangement with three-dimensional conformal radiation therapy (3DCRT) without interruption or significant adverse effects (► Fig. 2). She continued medical management for panhypopituitarism and psychiatric disturbances, and physiotherapy for motor weakness, memory and speech. At 2.5 years postradiation, she had significant improvement in lower limb power (¾), right eye vision (finger counting at 3 m), left facial, and oculomotor nerve function, while left eye vision was unchanged (finger counting at 0.3 m), and CEMRI showed stable disease.

We further evaluated possible fetal doses from therapeutic cranial radiation in vitro to guide decisions on fetal risk in future scenarios. CT images of an anthropometric Atom female phantom (CIRS, Tissue simulation and Phantom Technology, 900 Asbury Ave, Norfolk, Virginia, United States) were acquired on Philips Big Bore 4D-CT and fused with the CT images of the given patient in the Eclipse planning system (Version 11.0, Varian Medical Systems, Palo Alto, California, United States) (► Fig. 3). We simulated the treatment plan and delivery conditions, additionally placing three thermoluminescent dosimeters (TLDs) at three different positions on the abdominal surface (5 cm above umbilicus T1, at umbilicus T2, and 5 cm below umbilicus T3 in the midline) to measure the absorbed dose. At 26 to 28 weeks, the estimated position of the proximal part of

the fetus was approximately 50 cm from the lower border of the treatment field.

All the TLDs, LiF: Mg, Ti (TLD 100, REXON TLD Systems and Components, Ohio, United States) with cuboid shape (dimension: 1 mm × 1 mm × 6 mm) were annealed pre-RT to eliminate the previous history of residual information left by the procedure involving heating at 400°C for 1 hour followed by 105°C for 2 hours in a microprocessor-based heating oven.³ TLD sorting and element correction coefficient for each TLD were determined.⁴ RT doses delivered using 6 megavolts (MV) photon beam from a medical linear accelerator (Clinac DBX 1160, Varian, California, United States) were measured by A19 Exradin ion chamber with active volume 0.6 cc (ref. 92734, Standard Imaging, Middleton, Wisconsin, United States), Supermax Electrometer (ref. no. 90018, Standard Imaging, Middleton, Wisconsin, United States) and RW3 solid water phantom with density 1.04 g/cm³ (area 30 × 30 cm², thickness range 0.1–1 cm) at 5 cm depth, 10 × 10 cm² field size, and 100 cm source to surface distance. The monitor units required to deliver dose range 0.4 to 1,000 cGy were recorded, and a dose calibration curve for the given dose range for TLDs was obtained.⁵ Recording and analysis of thermoluminescence (TL) spectra from TLDs after RT were performed on REXON UL-300 readout system (Model UL 300, REXON TLD Systems and Components, Ohio, United States).

Post-RT annealing for TLDs was performed at 105°C for 15 minutes in the heating oven. The nonlinear curve fitting method already installed in graphical computer software Origin Pro (Version 8.5, OriginLab Corporation, Northampton, United States) was used for dose–TL response curve fitting for low dose range, that is, 0.4 to 30 cGy. Different models for nonlinear curve fitting (linear, exponential, sine, logistic, Gaussian) were used. Although the chi-squared values were very small for all mentioned models, the minimum value of chi-square ($\chi^2 = 0.00654$) was obtained for fitting with amplitude version of Gaussian peak function. The total dose recorded by these TLDs (T1, T2, and T3) for the entire planned dose of 5,400 cGy with the 3DCRT plan were 3.0599, 0.7135, and 1.9619 cGy, respectively. The possible lower dose of T2 versus T3 could be due to the placement of TLD nearly 1 cm dorsal (deep) in the umbilical region compared with the other TLDs placed on the abdominal surface.

Discussion

Intracranial chondrosarcomas are rare but carry an excellent prognosis (5-year survival 77% overall and 90% for well-differentiated).⁶ Adjuvant RT after incomplete resection dramatically reduces 5-year recurrence rates from 44 (after surgery alone) to 9% (after combined surgery and RT).⁶ Management involves multiple imaging studies (CT and MRI), surgical resection under general anesthesia, and adjuvant therapy based on grade and extent of resection. Before proceeding with investigations, it is crucial to test for possible pregnancy in any sexually active patient in the reproductive age group. In the setting of pregnancy, there is a need for modifications such as omission of CT scanning or other

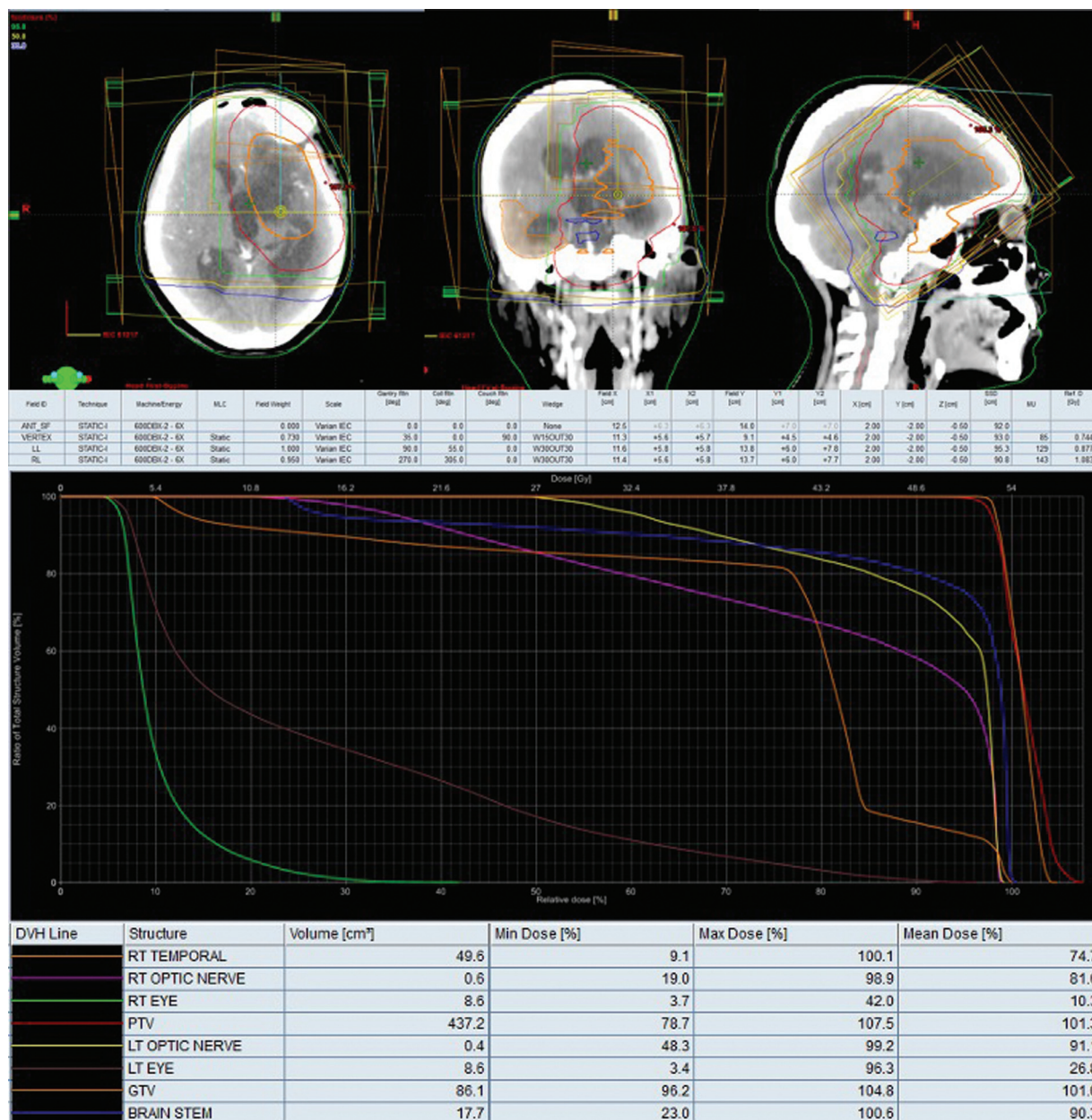


Fig. 2 Three-dimensional conformal radiotherapy plan images showing the planning target volume (PTV) (red outline) and the isodose levels 95% (green), 50% (yellow), and 30% (blue) in axial, coronal, and sagittal planes, for a planned dose of 54 gray (Gy) in 27 fractions to the target, delivering 357 monitor units. A noncoplanar vertex beam (~11 cm × 9 cm) with couch rotation was used in addition to two parallel opposed collimated beams (~12 cm × 14 cm). Dose volume histogram depicts doses received by PTV and organs at risk.

kilovoltage X-ray exposure, MRI studies without gadolinium, choice of antiepileptic agents (if presenting with seizures), and timing and type of anesthesia, patient positioning during surgery, as well as the need for fetal-maternal monitoring in the perioperative period. Although surgery is deemed safe during any trimester, it is preferable to delay it to the second trimester or later for asymptomatic patients with a stable disease course.⁷ Our patient had an undiagnosed pregnancy when she underwent investigations and surgery for her brain tumor; the disease adversely affected her PS and quality of life (QOL), while the investigations, medications, surgery under anesthesia without fetal monitoring, and need for RT risked fetal viability and normalcy.

Fetal risks from therapeutic radiation during pregnancy may either be stochastic (childhood malignancy, sterility) and independent of dose and POG, or deterministic and dependent on dose and POG at exposure. Doses of 10 to 20 cGy may cause fetal death, mental retardation, congenital defects, and growth retardation. The risk is highest in the first trimester and decreases considerably in subsequent trimesters.⁸⁻¹⁰ Unless there is an urgent need, RT should be postponed to the postpartum period. MTP is justifiable only if fetal dose estimates exceed 10 cGy. Cranial RT during pregnancy usually entails fetal exposures within the deterministic threshold due to large separation between treatment isocenter and fetus, and may be necessary, especially in



Fig. 3 Photograph with female Atom phantom with pelvic thermoluminescent dosimeters in situ.

aggressive malignancies. For situations where RT contributes significantly to disease control and QOL, RT may be planned in later pregnancy with necessary precautions, such as pretreatment phantom-based dose simulations, abdominal lead shielding to reduce fetal exposure, treatment plan modifications (linear accelerator with beam energy <10 MV preferred over cobalt-60, 3DCRT with minimal beam modifying devices preferred over intensity modulated RT, flattening filter-free beams).¹¹ During cranial RT in the second trimester, the fetal position is at a distance of 40 to 50 cm from the cranial field edge. At this distance, the contribution from external scatter exceeds that from internal scatter.¹² The major contributors to fetal dose include leakage from machine head (nearly 50%), wedge scatter, collimator scatter, and internal scatter; hence, shielding near machine head/patient neck may help curtail fetal exposure.¹³

Conclusion

In our patient, the surrogate fetal dose estimates during postpartum RT for the patient's disease were within acceptable limits (<10 cGy) and would have further reduced if reduction due to shielding was incorporated.¹⁴ The decision to terminate pregnancy/induce early delivery was taken after considering her poor general health and social support. In a fit patient with good PS and minimal neurologic symptoms, a well considered decision to continue the pregnancy would be justifiable with minimal fetal risk; decisions on the timing of RT would depend on the volume of residual disease and its rate of progression. In situations where the pregnancy was known earlier and due precautions taken during assessments and surgery to safeguard the fetus, if the patient had better PS with minimal sequelae from disease and surgery or if a near-complete resection was feasible, adjuvant RT could be delayed till delivery; a possible induction after 34 to 36 weeks after fetal lung maturity would ensure optimum maternal–fetal and oncologic outcomes. The patient and family must be counselled about the risks and gains, and their informed consent (high risk) is mandatory. Following delivery, the patient can be treated as any nonpregnant patient, and advice on breastfeed-

ing, contraceptive use, and modification of antiepileptics given. Follow-up imaging such as CEMRI poses no hindrance to breastfeeding. Even with favorable maternal and fetal health at delivery, long-term follow-up for both the mother (disease control, QOL, mental health, future pregnancies) and the child (structural and neurocognitive development, cancers, fertility) is recommended.¹⁵

Ethical Approval

All procedures performed were in accordance with the ethical standards of the institutional and/or national research committee and with the 1964 Helsinki declaration and its later amendments or comparable ethical standards.

Author Contributions

A.K.Y. contributed to concept, design, definition of intellectual content, literature search, data acquisition, data analysis, statistical analysis, manuscript preparation, and manuscript review. S.G. and R.M. were involved in concept, design, definition of intellectual content, literature search, clinical studies, data acquisition, data analysis, statistical analysis, manuscript preparation, manuscript editing, and manuscript review. R.S., A.C., and D.K. helped in definition of intellectual content, data acquisition, and manuscript review.

Conflict of Interest

None declared.

References

- 1 Cancer Stat Facts: Brain and Other Nervous System Cancer. Accessed October 13, 2022 at: <https://seer.cancer.gov/statfacts/html/brain.html>
- 2 Simon RH. Brain tumors in pregnancy. *Semin Neurol* 1988;8(03): 214–221
- 3 Yu C, Luxton G. TLD dose measurement: a simplified accurate technique for the dose range from 0.5 cGy to 1000 cGy. *Med Phys* 1999;26(06):1010–1016
- 4 Singh R, Oinam AS, Trivedi G, et al. A comparative study for surface dose evaluation in conventional treatment of carcinoma breast patients irradiated with Co-60 and 6 MV radiation beam. *J Cancer Res Ther* 2019;15(05):1035–1041
- 5 Singh R, Kainth HS. Effect of heating rate on thermoluminescence output of LiF: Mg, Ti (TLD-100) in dosimetric applications. *Nucl Instrum Methods Phys Res B* 2018;426:22–29
- 6 Bloch OG, Jian BJ, Yang I, et al. Cranial chondrosarcoma and recurrence. *Skull Base* 2010;20(03):149–156
- 7 van Westrhenen A, Senders JT, Martin E, DiRisio AC, Broekman MLD. Clinical challenges of glioma and pregnancy: a systematic review. *J Neurooncol* 2018;139(01):1–11
- 8 Donnelly EH, Smith JM, Farfán EB, Ozcan I. Prenatal radiation exposure: background material for counseling pregnant patients following exposure to radiation. *Disaster Med Public Health Prep* 2011;5(01):62–68
- 9 International Commission on Radiological Protection (ICRP) Pregnancy and medical radiation. ICRP Publication 84. *Ann ICRP* 2000; 30(01):1–43
- 10 NCRP. NCRP Report. Preconception and Prenatal Radiation Exposure: Health Effects and Protective Guidance. Bethesda, MD:

- National Council on Radiation Protection and Measurements; 2013
- 11 Labby ZE, Barraclough B, Bayliss RA, Besemer AE, Dunkerley DAP, Howard SP. Radiation treatment planning and delivery strategies for a pregnant brain tumor patient. *J Appl Clin Med Phys* 2018;19(05):368–374
 - 12 Stovall M, Blackwell CR, Cundiff J, et al. Fetal dose from radiotherapy with photon beams: report of AAPM Radiation Therapy Committee Task Group No. 36. *Med Phys* 1995;22(01):63–82
 - 13 Magné N, Marcié S, Pignol JP, Casagrande F, Lagrange JL. Radiotherapy for a solitary brain metastasis during pregnancy: a method for reducing fetal dose. *Br J Radiol* 2001;74(883):638–641
 - 14 Goyal S, Yadav A, Madan R, et al. Managing brain tumors in pregnancy: The oncologist's struggle with maternal-fetal conflict. *J Cancer Res Ther* 2022;18(01):5–18
 - 15 Maggen C, van Gerwen M, Van Calsteren K, Vandenbroucke T, Amant F. Management of cancer during pregnancy and current evidence of obstetric, neonatal and pediatric outcome: a review article. *Int J Gynecol Cancer* 2019. Doi: 10.1136/ijgc-2018-000061